Insert to

November/December 2016

CRST EUROPE

Cataract & Refractive Surgery Today

CONTINUING SURGICAL INNOVATION

ACROSS THE CATARACT, REFRACTIVE, AND THERAPEUTIC RANGES

THE COMPLETE REFRACTIVE CATARACT SURGERY PACKAGE

The Victus femtosecond laser, the Stellaris Vision Enhancement System, and the Versario Multifocal 3F IOL are three integral parts of a premium package.

BY JOAQUÍN FERNÁNDEZ, MD

For the past several years, I have been perfecting what I consider to be the complete refractive cataract surgery package that I can offer to my patients. Over this time, I have tried many different IOLs and many various technologies, all in effort to provide patients with safe, individualized care and the best possible refractive outcomes. My conclusion to date is that three integral parts to this equation include the Victus femtosecond laser (Technolas Perfect Vision, a Bausch + Lomb Company), the Stellaris Vision Enhancement System (Bausch + Lomb), and the Versario Multifocal 3F IOL (Bausch + Lomb).

INDIVIDUALIZED CARE

I firmly believe that one of the basic principles of refractive cataract surgery is being able to individualize patient care. Therefore, one reason that I trust the care of my patients to the Victus is that it allows me to customize the configuration of the capsulotomy and the pattern of the lens fragmentation based on the patient's cataract grade. Even the construction of the arcuate and corneal incisions can be individualized to the patient's ocular anatomy.

In addition to the customizability of the Victus, safety is another reason that I prefer laser-assisted cataract surgery (LACS) to manual cataract surgery. For example, with LACS, I have seen the rate of capsule-related complications virtually disappear. One important element to the success of the capsulotomy created by the laser is docking the patient's eye to the laser. By not using too much pressure, I can avoid endothelial folds, which would defocus the laser beam, and ensure a 100% free-floating capsulotomy.

WHY VICTUS?

The most valuable feature of the Victus—and something that is unique to the platform—is the incorporation of swept-source OCT. This feature is important not only in cataract surgery, but also in therapeutic and corneal procedures as well. As seen in a screen shot of the Victus software (Figure 1), the real-time surgery image is located on the left, the swept-source OCT image on the right, and the pressure gradient in the center. This screen is available during capsulotomy, lens fragmentation, and incision creation as well as during LASIK flap creation and all therapeutic procedures, such as penetrating and lamellar keratoplasties.

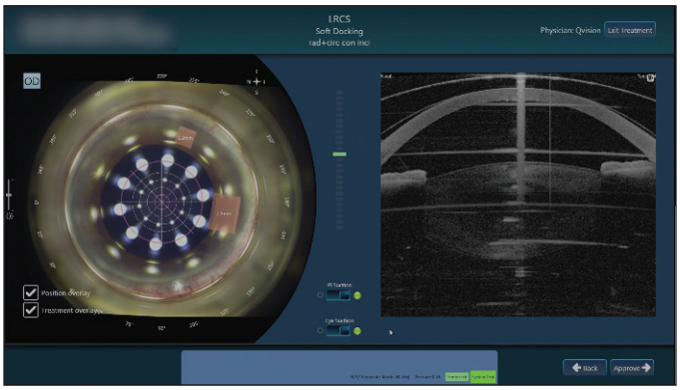

Figure 1. With the Victus, the real-time surgery image is on the left, the swept-source OCT image on the right, and the pressure gradient in the center.

When using the Victus to fragment the nucleus of a grade 2 cataract, I prefer to select a four radial, four circular pattern. For anything higher than a grade 2 cataract, I prefer a reticular pattern because it is easier to extract the nucleus with ultrasound.

Once the capsulotomy and fragmentation is achieved in a soft-docking mode, the eye is docked and the incisions are created. In my hands and with my instrumentation, I prefer a 2.5-mm main incision and a 1.2-mm paracentesis. After the femtosecond laser part of surgery is complete, the patient is moved to a separate operating room in which phacoemulsification and IOL implantation are performed.

PHACOEMULSIFICATION

For phacoemulsification, I prefer the Stellaris because it gives me the opportunity to perform microincision cataract surgery. As a result of the excellent anterior chamber stability, I can comfortably decrease my incision size without sacrificing the safety of the procedure. More features of the recently enhanced Stellaris can be found in the accompanying sidebar.

CONTINUING INNOVATION: STELLARIS ACTIVATE

Stellaris Activate, the next generation of phaco surgical systems, is designed to accommodate a surgeon's needs and surgical technique and to optimize chamber stability and control. Whether performing standard or microincision cataract surgery (MICS) procedures or as part of the femtosecond laser cataract procedure, Stellaris Activate provides the performance when needed. The latest updates on the Stellaris system include:

- New footpedal design and screen;
- DigiFlow Infusion Control;
- Common surgeon files transportable from Stellaris to Stellaris PC;
- Enhanced on-screen user controls and drop-down menus; and
- Enhanced messaging features for clarity and ease of use.

Stellaris Activate provides vacuum-based StableChamber fluidics with the option of DigiFlow pressurized infusion settings, with 76% of surgeons who have used the technology experiencing improved chamber stability compared with gravity feed.[1] Other components aimed at optimizing the chamber stability include the VFM StableChamber Tubing, designed to control and stabilize flow in MICS High Vacuum procedures; advanced hardware; and customizable software settings.

Furthermore, the Stellaris Active features an innovative wireless programmable footpedal with Dual Linear technology control for modulating several parameters with one footpedal.

1. Data on file with Bausch + Lomb.

For the past 2 years, I have performed all of my surgeries with the 30º Zero Phaco I/A handpiece (Bausch + Lomb Storz Ophthalmic Instruments). This sterile, single-use handpiece is an important tool in order to prevent toxic anterior segment syndrome. The silicone irrigation sleeve increases wound sealability and works perfectly with the Stellaris platform.

Once inside the anterior chamber, in order to avoid opacification, it is important to rotate the nucleus and then perform a soft but decisive resection. I aspirate the cataract, beginning in the periphery with the epinucleus, in order to remove the softer material first, and travelling to the center of the nucleus.

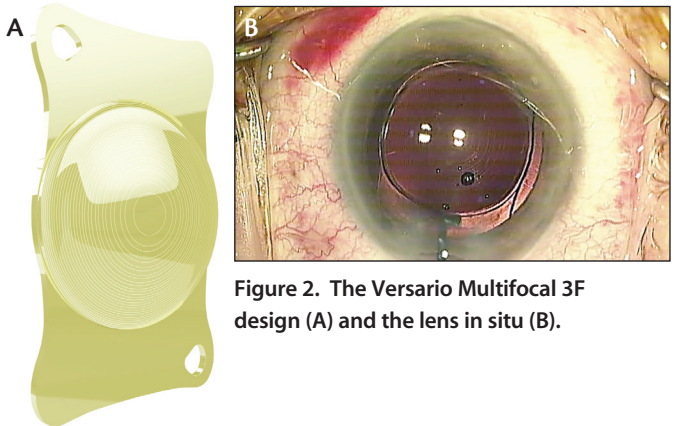

Figure 2. The Versario Multifocal 3F design (A) and the lens in situ (B).

IOL SELECTION

Two of the newest IOL categories are trifocal and extended depth of focus (EDOF) lenses. On one hand, trifocal IOLs probably provide the best near vision, but there is the chance for dysphotopsias. On the other hand, EDOF lenses reduce the incidence of dysphotopsias, but they do not provide the same level of near vision as trifocal IOLs. Alternatively, the Versario Multifocal 3F (Figure 2), in my opinion, provides the best of both worlds because the near and intermediate additions are placed at the spectacle plane, at around 45 cm (2.20 D) and at 90 cm (1.11 D), respectively.

This lens is a patient-friendly, universal platform, and, in my experience, patients have been extremely happy with their results. I have noticed that this lens is the best option for patients who are heavy users of mobile devices, tablets, and computers.

CONCLUSION

Refractive cataract surgery is not a science, but it does require that surgeons pay special attention to offering patients individualized care. I believe that LACS with the Victus, phacoemulsification with the Stellaris, and IOL implantation with the Versario Multifocal 3F are key components of the process. I feel comfortable offering patients this complete refractive cataract surgery package, as I am confident they will achieve excellent postoperative outcomes. ■

Joaquín Fernández, MD
■ Medical Director, Qvision, Almería, Spain
■ joaquinfernandezoft@qvision.es
■ Financial interest: None acknowledged

A WORTHY TRIO

The Victus, Stellaris, and EyeCee One Preloaded IOL contribute to the success of premium cataract surgery.

BY HOSAM KASABY, MBChB(Hons), DO, FRCS, FRCOphth

I have worked in a private hospital setting in the United Kingdom for 21 years. In our hospital, which is located approximately 20 miles outside of London, we perform 1,500 cataract surgery procedures annually. We have been performing laser-assisted cataract surgery (LACS) with the Victus femtosecond laser (Technolas Perfect Vision, a Bausch + Lomb Company) for 3 years. In a lot of those cases, I use the laser in combination with the Stellaris Vision Enhancement System and the EyeCee One Preloaded IOL (both by Bausch + Lomb). Below I share insights into my experience with this trio of products providing superb postoperative outcomes.

LASER PROCEDURE

One thing that I particularly like about the Victus in comparison to other laser platforms for cataract surgery is its friendly curved patient interface. I simply place it on the eye, center it, and engage the suction. After suction is engaged, the docking is simply a matter of raising the patient to meet the cone of the interface. Due to the system's Intelligent Pressure Sensors, which provides real-time monitoring of the curved patient interface with the eye, a soft dock is achieved. Designed to reduce applanation of the cornea, this feature minimizes the presence of wrinkles on the cornea.

Another benefit of the Victus is that the process itself is virtually painless to the patient. In a recent study comparing patient comfort during LACS with the Victus platform to patient comfort during standard cataract surgery, the majority of patients preferred the laser. In all 20 patients enrolled in the study, LACS was performed in one eye and standard cataract surgery in the other.

Capsulotomy. The automatic recognition software of the Victus femtosecond laser works exceptionally well. In every LACS case I perform, I switch off the treatment overlay during capsulotomy in order to better see the surgical field. While the laser capsulotomy is being performed, I confirm the presence of air bubbles all around the capsulotomy in order to confirm completeness and also look at the OCT image breaks in order to verify that the capsulotomy is complete. This portion of the procedure lasts only a few seconds.

Lens prefragmentation. Next, I perform laser lens prefragmentation. For moderately dense cataracts, I choose the cross-hatch (grid) pattern. First, the air bubbles appear at the deepest part of the lens and travel upward toward the anterior capsule. This step is also quick, lasting around 12 seconds.

In our hospital, the laser suite and operating room are adjacent. Once lens fragmentation is complete, a member of our surgical staff leads the patient from the laser suite and into the operating room for phacoemulsification and IOL implantation.

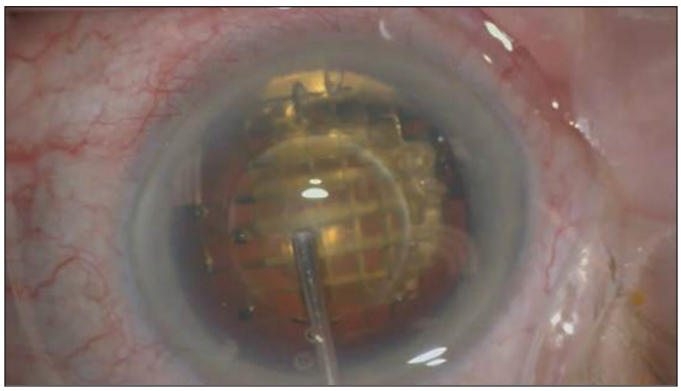

Figure 1. Fragmentation of the prechopped nucleus.

SURGICAL PROCEDURE

In the majority of LACS case that I have performed, I have not found any significant subconjunctival hemorrhage from the suction ring of the Victus. After opening the corneal wound, I first collapse the center of the anterior capsule by pushing on it with a viscoelastic cannula in order to ensure full separation of the capsulotomy. Then I continue pressing/passing the cannula through one of the central grooves made by the laser and inject OVD deep into the groove in a technique that I call *visco chop* (Figure 1). This splits the lens in half and releases the air from behind the nucleus. The releasing of the air aids in hydrodissection and avoids capsular rupture.

Hydrodissection. At this point, the lens is really mobile, and hydrodissection can be easily achieved. As an aside, I have found that, with LACS, hydrodissection tends to be a little easier than it is during standard cataract surgery. I believe this is because of the way the air disrupts the cortex. I then chop the nucleus in half again, creating four quadrants of similar size.

Phacoemulsification. For denser cataracts, I would not use a zero phaco technique. However, the amount of phacoemulsification I need to remove the cataract is considerably less than it would have been without prefragmentation with the Victus.

I use high vacuum (600 mm Hg), which most people would frown at, but am able to maintain a perfectly stable anterior chamber. With the high vacuum, I only use very low ultrasound power.

Figure 2. The EyeCee One Preloaded IOL.

Irrigation/aspiration. Because the lens is almost welded around the edge of a laser capsulotomy, irrigation/aspiration can be a little more challenging than it is during a manual cataract surgery procedure. Although this stage can take a little longer than normal, the Capsule Guard I/A silicone tip (Bausch + Lomb) is helpful because it is gentle and kind to the capsule.

IOL implantation. I implant the EyeCee One Preloaded IOL (Figure 2) with a single-handed technique. In my experience, it is the easiest and the most friendly preloaded injection system available today because it requires only two steps: First, the cartridge of the injector is filled with a low molecular weight OVD; second, the plunger is engaged to release the IOL from the cartridge. Although the recommended incision size is 2.4 mm, in my experience, the EyeCee preloaded injector fits through a 2.2-mm incision and injects the IOL into the bag in a single continuous motion.

During injection, I support the eye with a Sinskey hook placed through the paracentesis. As the IOL unfolds into the eye, I use the plunger to manipulate the lens into the capsular bag, avoiding the need to come out of the eye to get another instrument.

As has been my overall experience with the EyeCee to date, the lens centers beautifully. With the haptics located 90° to the optic, centration of this lens is truly amazing.

CONCLUSION

The more Bausch + Lomb products I use, the more I realize how well they work together to produce excellent refractive results. This is true in not only standard cataract surgery but also in premium cataract surgery. I have had much success with the trio of the Victus femtosecond laser, the Stellaris Vision Enhancement System, and the EyeCee One Preloaded IOL, and I envision using this combination in many more cases. ■

Hosam Kasaby, MBChB(Hons), DO, FRCS, FRCOphth
- Consultant Ophthalmic Surgeon, Southend University Hospital NHS Foundation Trust, United Kingdom
- kasaby@aol.com
- Financial interest: None acknowledged

MASTERING A DIFFICULT KERATOPLASTY PROCEDURE

In this case, the Victus was instrumental in achieving a good postoperative result.

BY LOUIS HOFFART, MD, PHD

It has been more than 10 years since I performed my first femtosecond-assisted keratoplasty procedure. Back then, I was using the Femtec femtosecond laser (20/10 Perfect Vision) with good outcomes. Difficult cases could be challenging to complete successfully, however, and surgery took a considerable amount of time.

Femtosecond laser technology has come a long way in the past 10 years, but difficult cases can still be nerve-wracking. Luckily, with the Victus femtosecond laser (Technolas Perfect Vision, a Bausch + Lomb Company), I can more successfully manage difficult cases without too many alterations to my standard technique and without the need to spend too much extra time in the operating room. Below I describe a specific case in which surgery was challenging and the Victus was instrumental in the final outcome.

CASE PRESENTATION

A 60-year-old man presented with corneal endothelial decompensation after PKP. On examination, extensive superficial and deep neovascularization was present. I counseled the

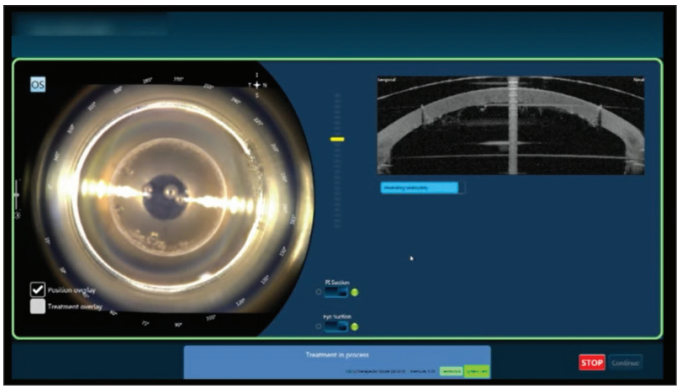

Figure 1. Trephination with the Victus femtosecond laser.

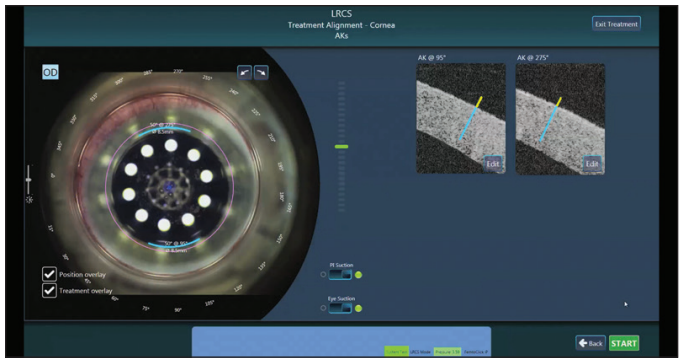

Figure 2. Example of arcuate treatment alignment software with the Victus femtosecond laser.

patient that a regraft by subsequent PKP was required, and surgery was scheduled.

The main difficulty in this case of femtosecond-assisted PKP was finding the center of the trephination on the previous graft, which could only be achieved by marking the patient's eye under the microscope before performing the laser cut. Also, because the laser energy is absorbed locally, the cutting of corneal vessels could create tissue bridges, requiring scissors to achieve the corneal cut.

RECAPPING THE PROCEDURE

Preparation and cutting of the corneal graft. First, the graft was mounted onto the artificial chamber and the patient interface was docked. Then, the graft was cut. This step can be completed in about 25 to 40 seconds, depending on the settings of the laser (Figure 1). Furthermore, the OCT function of the Victus allows me to see when trephination is complete.

One nice feature of the latest Victus model is that I have the ability to re-centrate the corneal graft trephination onto the patient. In this case, I chose to center the trephination from the limbus of the corneal scleral rim.

Examination. The next step of the procedure was to examine the patient under anesthesia (either general or peribulbar can be used) in order to determine the placement of the graft. In this case, the amount of anesthesia was inadequate, as I could detect mobility of the eye. Luckily, I was still able to complete the examination and locate the areas of neovascularization on OCT.

After examination, I decided it was best to re-centrate the corneal graft in the exact place of the previous trephination. With other femtosecond lasers, I always found that this was really difficult to perform, as it required many manipulations of the eye and the patient interface to ensure exact placement of the trephination. In my experience with the current Victus software, however, it is far easier and faster to perform this kind of procedure. I can locate the wound of the previous graft and, when necessary, offset the trephination with just a few clicks on the software.

Trephination. Under the lateral microscope, the trephination was completed with no problems. As is the case with any neovascularization, I had to take cutting scissors to fully complete the cut in this area. Once completed, I took note that the new trephination was smooth, complete, and exactly in the place of the previous trephination. I also noted that the cornea was clear.

Suturing. I took back the corneal scleral rim onto the artificial chamber and, because of the smoothness of the cuts, I was able to clearly see where to place the corneal graft. I sutured the graft in place, and the procedure was complete.

ASTIGMATISM CORRECTION

Astigmatism can be a major concern after keratoplasty. One nice feature of the Victus is that I can also perform intrastromal astigmatic keratotomy. In this case, I was able to reduce the patient's irregular astigmatism by performing an asymmetric intrastromal astigmatic keratotomy.

Several benefits of the Victus arcuate incision software (Figure 2) are that I can select the settings of each incision separation, that I have OCT visualization of each arcuate incision, and that I can choose exactly the depth of the incision. Furthermore, the procedure can be completed in as little as 10 to 15 seconds, without opening the anterior corneal surface.

CONCLUSION

I was happy with the outcomes in this difficult case, and it is a great example to highlight the capabilities of the Victus femtosecond laser. ■

Louis Hoffart, MD, PhD
- Ophthalmology Department, Hôpital d'adultes de la Timone, Marseilles, France
- louis.hoffart@ap-hm.fr
- Financial interest: None acknowledged

A WINNING COMBINATION

Together, the Victus and Teneo 317 laser systems can achieve clinical precision.

BY ROBERTO BELLUCCI, MD

It is no secret that today, in order to achieve the most precise outcomes in refractive surgery, the preferable method of flap creation is with a femtosecond laser. Taking this one step further, selecting the proper treatment for the individual patient and executing precise surgery are other key indicators of a successful procedure.

Below I demonstrate the advantages of using two lasers, the Victus femtosecond laser and the Technolas Teneo 317 excimer laser (both by Technolas Perfect Vision, a Bausch + Lomb company), in a refractive surgery case that required outside-the-box thinking.

CASE PRESENTATION

A 48-year-old woman with 4.50 D cylinder in her right eye (Figure 1A) and 1.00 D sphere in her left (Figure 1B) presented for refractive surgery in August 2016. The patient's right eye was sub-amblyopic, with 0.2 logMAR BCVA. Having required spectacles for her entire life, she was now also facing symptoms of presbyopia. After discussing the surgical options with her, we decided it was best to perform LASIK in her right eye and Supracor in her left to improve both distance and near vision. As I explained, this combination would allow her to achieve unaided vision for distance, while some optical correction could be required for near vision.

Flap creation. I created both flaps with the Victus femtosecond laser. I like this laser for several reasons, the most attractive of which is the ability to double-follow the corneal dissection, both from above with the embedded camera and from the side with the laser's swept-source OCT. In this particular case, the spacing of the laser shots and the laser energy were reduced from the standard 750 nJ/5.8 µm to 700 nJ/6.2 µm because the patient did not wear contact lenses and was almost 50 years old.

LASIK treatment. I no longer mark the cornea, as this is unnecessary with the femtosecond laser. One trick to easily opening the flap and to achieving a seamless iris registration with the Teneo is to partly open the sidecut of the flap and remove the air bubbles created by the femtosecond laser. This allows me to properly engage the Teneo's eyetracker with iris recognition before dissecting the flap, which is achieved not only precisely but also quickly.

After folding the flap back with a Seibel Lasik elevator (MMSU 1172; Malosa Medical), I prepared the eye for the treatment. I find it useful to first dry the conjunctiva. Then, with the laser compensating for every eye movement, the ablation was performed. The new plume evacuator of the Teneo 317 contains eight nozzles that are distributed homogenously over 270º. This design

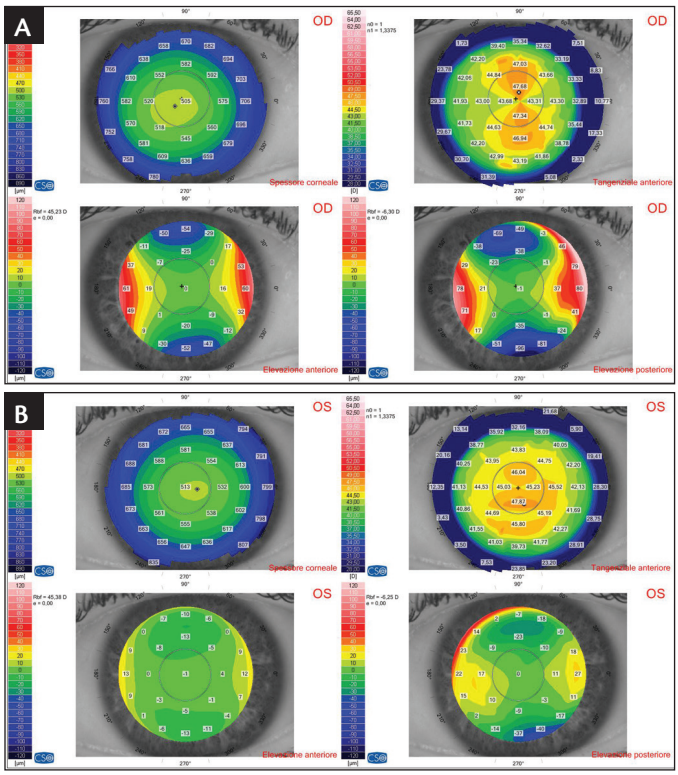

Figure 1. Right (A) and left (B) eyes preoperatively.

ensures that controlled aspiration is achieved and that a uniform laser beam is delivered throughout the duration of the ablation. Furthermore, in my opinion, the plume evacuator also clears the operating field, which is extremely helpful for patients, especially those who are anxious or nervous about undergoing surgery.

Once the ablation was achieved, I checked the status of the flap and repositioned it with irrigation. After I dried and re-wet the conjunctiva, I applied downward pressure to the flap to make sure that it was perfectly adherent to the cornea.

Supracor treatment. Supracor is a LASIK procedure for presbyopes, available on the Teneo 317 excimer laser. A small central steepening of the cornea is created to provide the wanted near addition. Again, with irrigation, I squeezed away the air bubbles via the small opening of the flap sidecut in order to engage the eyetracker. Then, I activated the iris recognition via the the graphical user interface. For this, the patient's iris reference data was preloaded from the Zyoptix Diagnostic workstation (Technolas Perfect Vision, a Bausch + Lomb company). I then opened the

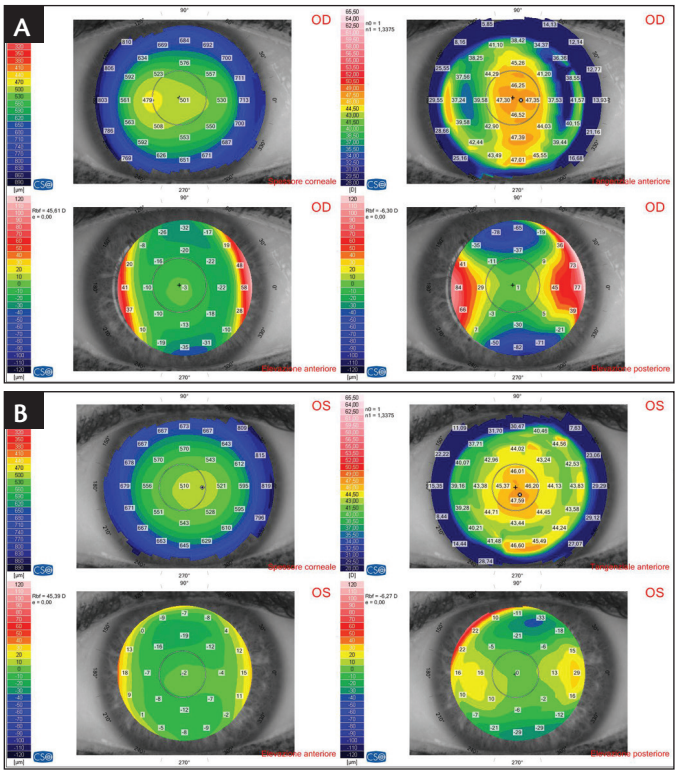

Figure 2. Right (A) and left (B) eyes 2 months postoperatively.

flap. Another useful tip for this step is to take your time, lifting the flap in several steps in order to decrease the stress exerted on the flap and on the cornea. I have found this to be especially effective with flaps created in patients under 30 years of age.

Once the eyetracker was engaged, I performed the ablation. I referenced the Purkinje images during both fixation and the treatment to ensure that the ablation was perfectly centered.

On postoperative day 1, the patient was already satisfied with her results. The refraction in her right eye improved from 4.50 D to -0.50 D of astigmatism and UCVA from 1.0 to 0.16 logMAR (Figure 2A). As intended, in the patient's left eye, the Supracor treatment produced a small central near add (Figure 2B). The patient achieved 0.00 logMAR UCVA for distance and for near and, even though the Supracor procedure was performed in only one eye, she was completely spectacle independent also for near vision. Over the following weeks, the result was maintained. Several years later, she is still completely spectacle independent.

TOP THREE ADVANTAGES: VICTUS AND TENEO 317

In my experience, the top three advantages of the Victus are:

No. 1: Docking is easy because of the fixed two-piece curved patient interface. In corneal applications like LASIK, the Victus docks with full contact to minimize the possibility of eye tilt or distortion, meaning that precise alignment is achieved every time and also that the natural shape of the eye is maintained better than on a fully applanating system. Alternatively, in cataract surgery applications, soft docking is maintained by a thin liquid layer separating the cornea from the curved interface, thus avoiding corneal folds.

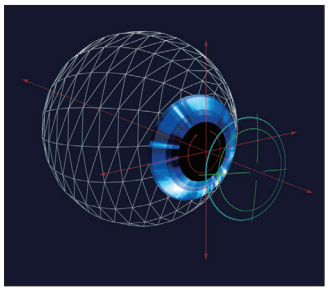

Figure 3. The ACE Eyetracker with coaxial camera.

No. 2: The treatment zone can be established depending on the patient's anatomy. In the case described herein, the treatment was centered in the middle of the suction ring; however, when some eye tilt develops at docking, the laser is still able to start working on one side of the cornea, compensating for the decentration, in order to finish treatment.

No. 3: The energy is perfectly focused. With the Victus, the applied energy is perfectly focused at a steady distance of 110 µm from the curved patient interface. The laser incorporates a specific device that varies the focal length during treatment progression in order to increase precision and decrease the total energy required.

In my experience, the top three advantages of the Teneo 317 are:

No. 1: The laser's SyperSync ensures that the scanner, eye tracker, and laser are perfectly matched. As a result, I can be confident that all aspects of the laser will perform seamlessly.

No. 2: The new-generation ACE Eyetracker incorporates a coaxial camera (Figure 3). The incorporation of a sophisticated, multidimensional eyetracker helps me to achieve low treatment rates.

No. 3: The laser produces a smooth ablation, thanks to its new spot distribution pattern. Instead of using a treatment card to control the shape of the truncated Gaussian laser beam, now an optical element inside the laser arm of the Teneo 317 creates the shape. Furthermore, the updated laser pattern, with a low energy soft spot of 1 mm that overlaps once every 16 pulses, minimizes the thermal effect of the laser.

CONCLUSION

The precision of the Victus and of the Teneo is unparalleled. In my practice, I now perform all standard LASIK treatments with the Victus for flap creation and the Teneo 317 for ablation. Results to date have been excellent, and patient satisfaction has remained high.

I am continually impressed by how fast this procedure is in my own clinical practice. And, as compared with other lasers, I choose the combination of the Victus and the Teneo 317 because of its accuracy in terms of the correction it performs. ■

Roberto Bellucci, MD
- Chief Ophthalmic Surgeon, Unità Locale Socio Sanitaria No. 20, Verona, Italy
- robbell@tin.it
- Financial disclosure: Consultant (Bausch + Lomb)